

1501

Trachoma 75

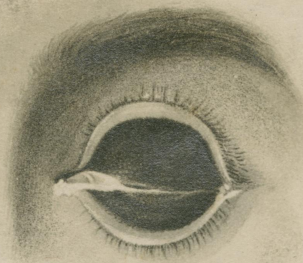


FIG. 1.—ACUTE TRACHOMA, WELL DEVELOPED WITH GENERAL DISTRIBUTION OF THE GRANULATIONS IN BOTH THE SUPERIOR AND INFERIOR CONJUNCTIVAE.
(U.S. PUBLIC HEALTH SERVICE)

#476

1502

Trachoma 76

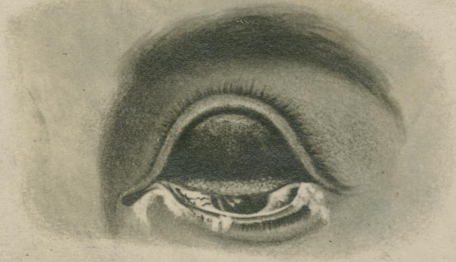

FIG. 2.—TRACHOMA—BEGINNING CICATRIZATION.
(U.S. PUBLIC HEALTH SERVICE)

#477

1503

Trachoma 77

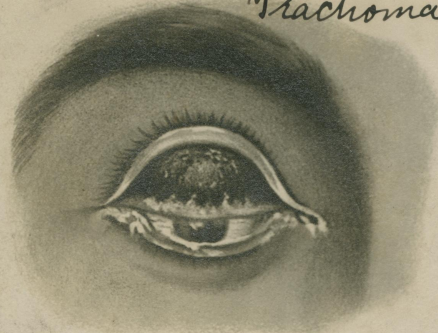


FIG. 3.—TRACHOMA—CICATRIZATION WELL MARKED.
(U.S. PUBLIC HEALTH SERVICE)

#478