


ay" 1795



This girl, 18 years of age, states that she has been unable to open her eyes on account of trachoma for about 10 years and at the time this photograph was taken, Dec. 29, 1915, was an inmate of the poor house in Muhlenberg County, Kentucky.  
U.S. Public Health Service.

#599

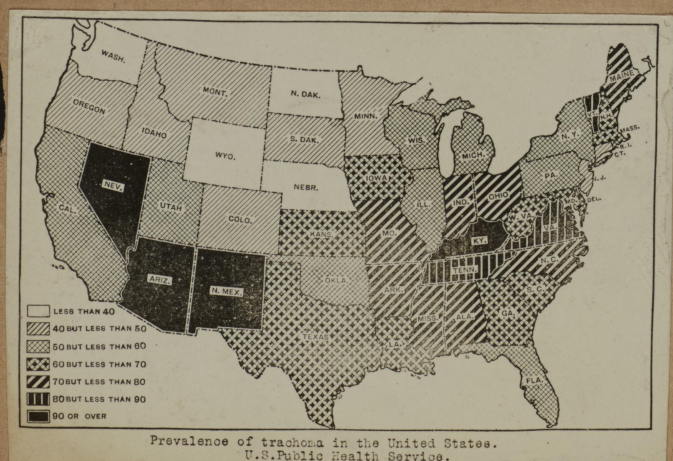
1796



Trachoma case showing one eye that has been operated on and the other that has not.  
U.S. Public Health Service.

#600

1797



#601